

# Optimising wound healing in an unstageable pressure ulcer using Flaminal®

Lourdes Rivera & Maria Rebouco, Tissue Viability Nurse Clinical Nurse Specialists (TVSN), Whipps Cross Hospital, Barts NHS Trust

## Introduction

Pressure ulcers are highly prevalent and challenging wounds. They are a major burden to the individuals, impacting their physical, mental, and social wellbeing. A pressure ulcer represents localised injury to the skin and/or underlying tissue usually over a bony prominence, as a result of prolonged pressure or pressure in combination with shear. Individuals who develop pressure ulcers often require long term interventions, representing a large economic burden to the health care system.

## The Patient

This case study involves a 66-year-old female with a medical history of Asthma, Huntington's Disease, and a Depressive and Compulsive disorder. She was known to the psychiatric team presenting with episodes of self-neglect and hoarding tendencies, that had previously resulted in multiple falls, sustaining fractures of the ankle on two occasions. The patient was admitted to hospital after a fall at home with a subsequent long lie on the floor.

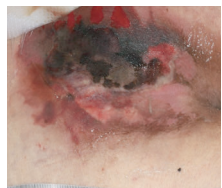


Image 1 - 24/11/23

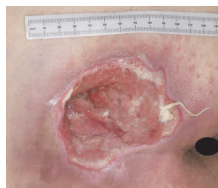

Image 2 - 21/12/23

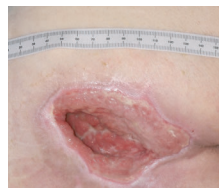

Image 3 - 27/12/23

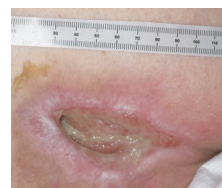

Image 4 - 23/1/24

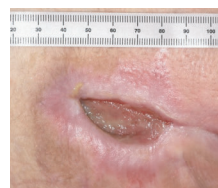


Image 5 - 7/2/24

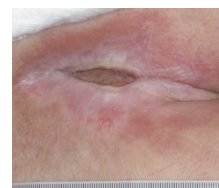


Image 6 - 16/2/24

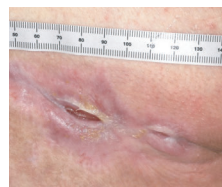


Image 7 - 11/3/24

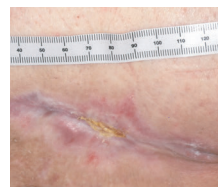

Image 8 - 20/3/24

During the emergency department assessment, the patient presented with multiple areas of pressure damage, the most extensive being that of the sacrum, inclusive of the upper buttocks, categorised as unstageable; a term describing an ulcer of unknown depth, due to the ulcer bed being obscured by devitalised tissue<sup>(1)</sup>.

The Tissue Viability Specialist Nurse's (TVSN) assessment highlighted that the pressure ulcer dimensions were 11cm (L) x 8.5cm (W) with 100% necrotic tissue evident (image 1). There was suspected localised infection with minimal amounts of haemoserous exudate, no malodour and no obvious undermining. The surrounding tissue was erythematous with noted induration on palpation. An MRI was completed which proved negative for osteomyelitis but positive for infective myositis of the right gluteal muscle.

## Method

The TVSN's aim was to facilitate debridement of the devitalised tissue in order to encourage healthy granulation tissue and to reduce the risk of infection. Initial treatment included the use of a honey based primary dressing, which was followed by sharp debridement, as the pressure ulcer had begun to show evidence of deterioration with the presence of large volumes of purulent exudate and malodour coupled with systemic signs of infection. Post sharp debridement the pressure ulcer was verified as a category 4 with muscle and tendon visible and palpable bone, inclusive of 60% granulation tissue (image 2). At this point there was apparent undermining. Tissue sample wound swabs revealed colonisation of *Escherichia coli*, *Enterococcus faecalis*, *Enterococcus Faecium* and *Peptostreptococcus* species and IV antibiotic therapy was initiated. The patient was commenced on Flaminal® Hydro a primary dressing with antimicrobial protection, covered by a Hydrofibre to keep the Flaminal® in place and a secondary silicone foam adhesive. Dressing change frequency was advised every 2 days, dependent on exudate levels.

## Result

The suggested wound management plan continued throughout the wound healing continuum and remained free from infection. Flaminal® Hydro maintained an optimum moist wound healing environment whilst preserving wound edges by absorbing excess exudate and debris into the gel matrix. The pressure ulcer continued to decrease in size at each dressing change (images

3-8) and at 13 weeks complete healing was achieved. The use of Flaminal® Hydro primary dressing exceeded the Tissue Viability Specialist Nurse's aims and facilitated an uninterrupted wound healing trajectory.

## Discussion

Patients with pressure ulcers typically experience pain and increased risk of infection, morbidity and mortality rates<sup>(2)</sup>. Treatment of pressure ulcers is costly, averaging between £1214 to £14,108 dependent on severity and associated complications<sup>(3)</sup>. Management is a prolonged process and should have a goal based on the ulcer's severity. For instance, category 1 and 2 pressure ulcers can be healed with conservative care, however, those of category 3 and 4 require longer times to heal and may sometimes need surgical revisions<sup>(4)</sup>. In pressure ulcer management, it is crucial to implement an individualised treatment plan, taking into consideration the knowledge and skills of the clinician alongside regular repositioning, adequate nutrition and hydration, regular toileting to prevent wound contamination, amongst further nursing care.

## Conclusion

This case study demonstrates the clinical effectiveness of Flaminal® Hydro as a protective antimicrobial agent and confirms its ability to facilitate exudate management whilst supporting a moist wound healing environment. As Flaminal® products are non-cytotoxic to healthy cells, this gives rise to its versatility in the ability to be used for the duration of the wound healing journey; hence supporting continuity and a simplistic but effective wound management plan. The Tissue Viability Nurse concluded that treatment aims were exceeded and that use of Flaminal® products would be incorporated in future wound management cases.

## References

1. National Pressure Ulcer Advisory Panel (NPUAP). European Pressure Ulcer Advisory Panel (EPUAP), Pan Pacific Pressure Injury Alliance (PPPIA). International Pressure Ulcer Guidelines.
2. Borojeny LA, Albatineh AN, Dehkordi AH, Gheshlagh RG (2020) The incidence of pressure ulcers and its associations in different wards of the hospital: A systematic review and meta-analysis. *Int J Prev Med* 11(1):171. <https://wounds-uk.com/wp-content/uploads/sites/2/2023/02/2ab3f317df7eb8c4a6b0ea6465e134a9.pdf>
3. Dealey C, Posnett J, Walker A (2012) The cost of pressure ulcers in the United Kingdom. *J Wound Care* 21(6):261-266. <https://doi.org/10.12968/jowc.2012.21.6.261>. PMID: 22886290.